

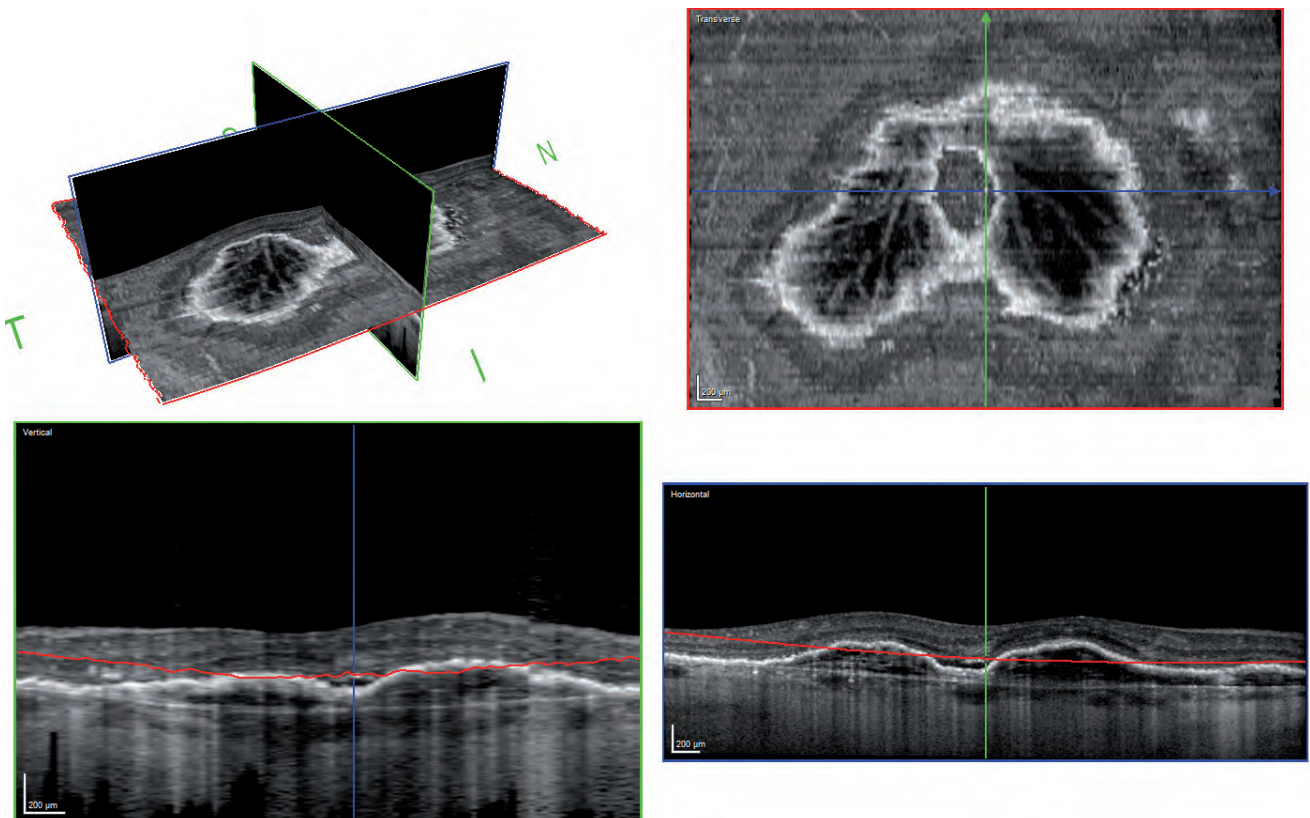
“The Transverse Section Analysis gives a whole new perspective on pathologies and provides an important tool to identify diseased areas and interactions between different retinal and choroidal layers.”

G. Coscas, MD

The Transverse Section Analysis adds a new perspective on pathologies to the SPECTRALIS giving the user a comprehensive and easy-to-obtain view of high-resolution OCT volume scans in a single window. Pathologies can quickly be quantified and correlated to anatomic structures seen on simultaneously acquired real time tracked cSLO images.

The TruTrack Active Eye-Tracking of the SPECTRALIS avoids motion artifacts and together with automatic real time (ART) image averaging ensures high quality transverse sections.

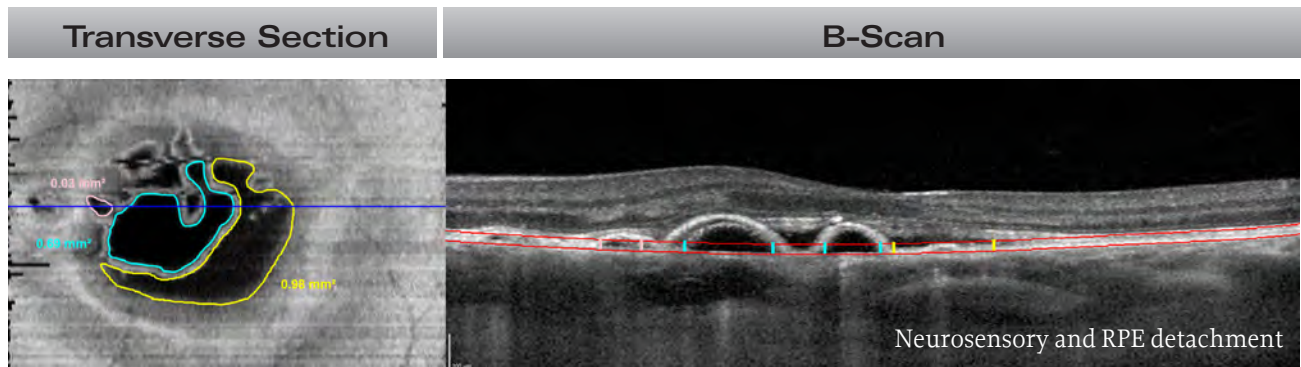
A Broader Spectrum of OCT Analysis



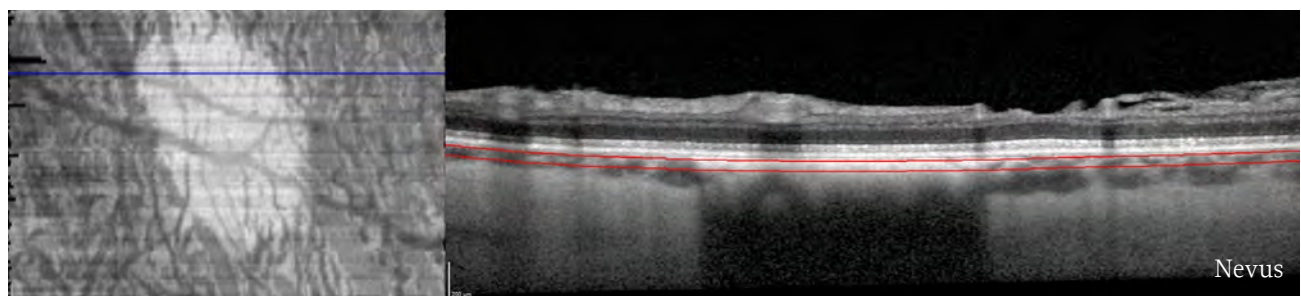
The Transverse Section Analysis gives the user a 3D view for easy orientation. It displays the Transverse Section as well as the corresponding vertical and horizontal OCT scans. The Transverse Sections can automatically be aligned parallel to Bruch's membrane or ILM. The example shows a new vessel network in a vascularized PED.

Versatility of Transverse Sections

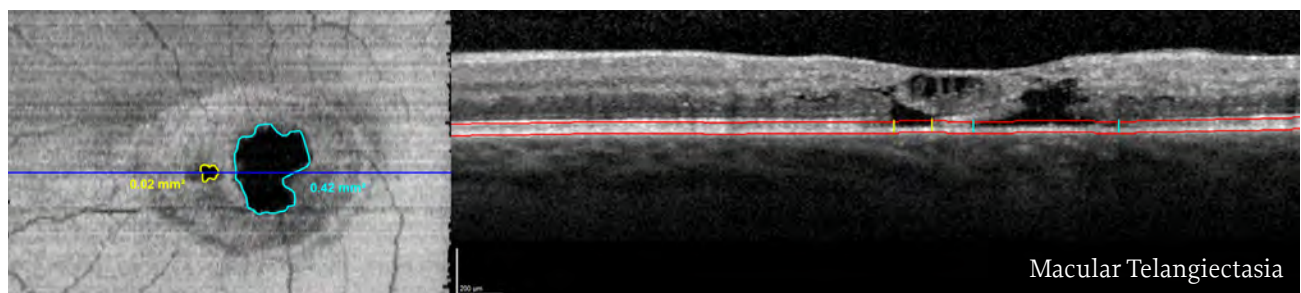
The Transverse Section Analysis offers several analysis options and measurement tools to fully visualize and quantify the extent of pathologies.



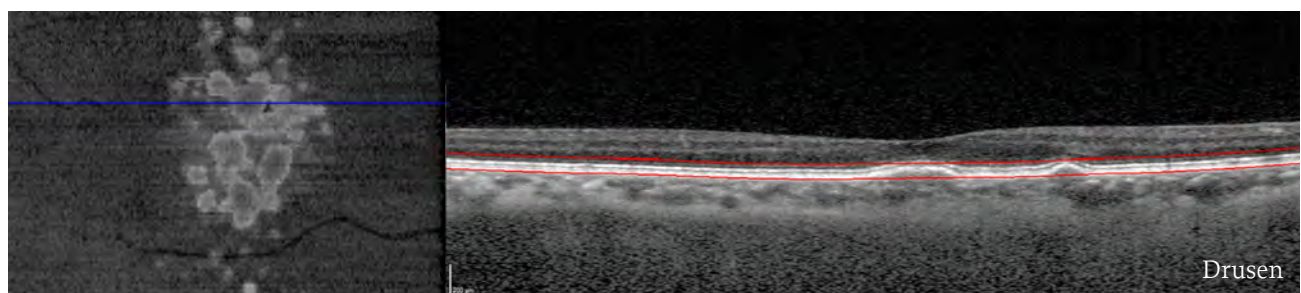
The area of subretinal and sub-RPE fluid can easily be quantified. Treatment effects can be monitored in the Transverse Section Analysis based on AutoRescan follow-up exams.



Enhanced Depth Imaging (EDI) OCT scans give great insight deeper into the choroid and make it possible to visualize different sub-RPE structures.



The complete area of photoreceptor degeneration is shown.



The extent of drusen can quickly be visualized.

Images courtesy of:

G. Coscas, MD, Paris, France - F. Coscas, MD, Paris, France - M. Mauget-Faysse, MD, Paris, France - E. Souied, MD, Créteil, France