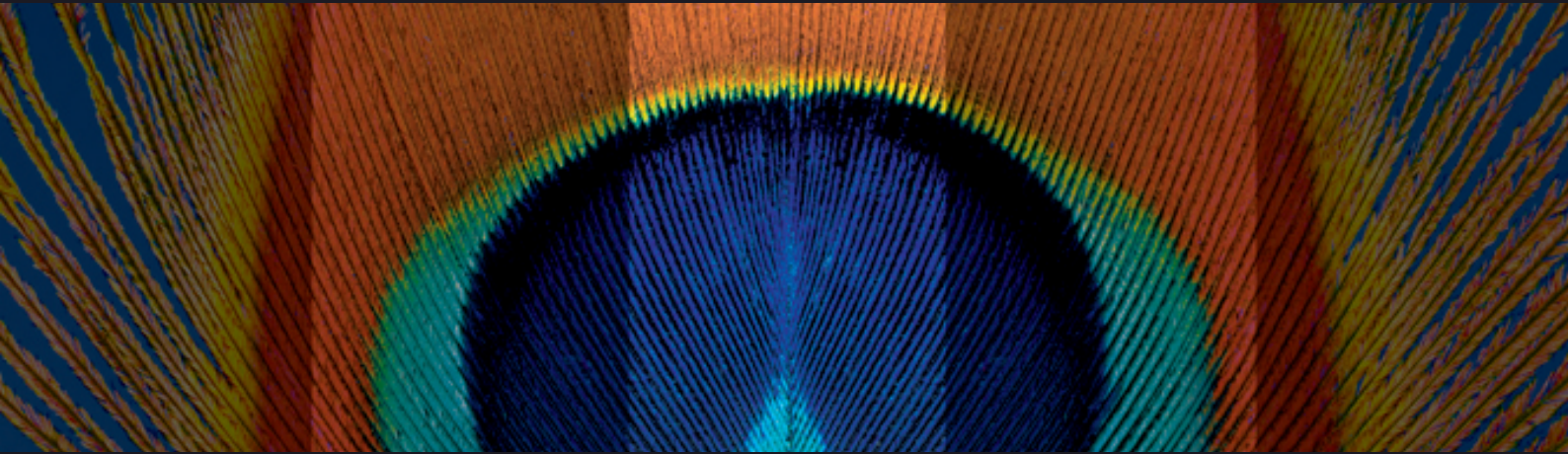


The Technology of Fusion



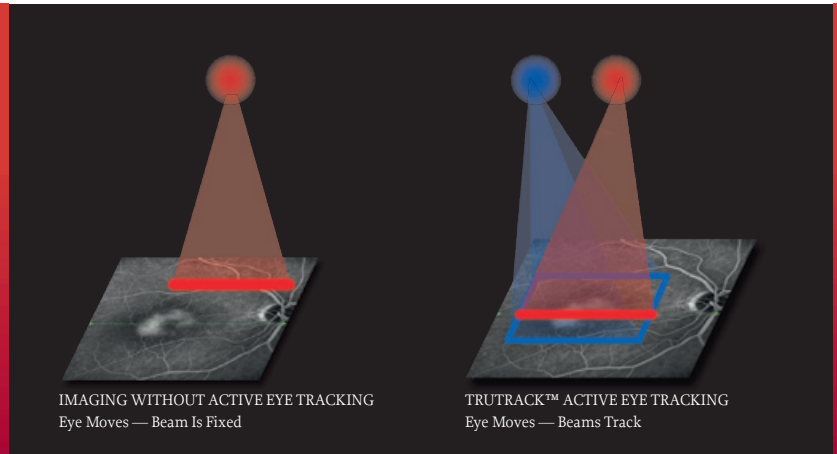
**SPECTRALIS<sup>®</sup>**

**HEIDELBERG  
ENGINEERING**

# Tracking Laser Tomography - Two Technologies in One Device

"This technology is the only one of its kind that merges these two state-of-the-art diagnostic modalities. The precise, pixel-to-pixel alignment of the cSLO and SD-OCT images is an exciting feature."

Frank G. Holz, MD

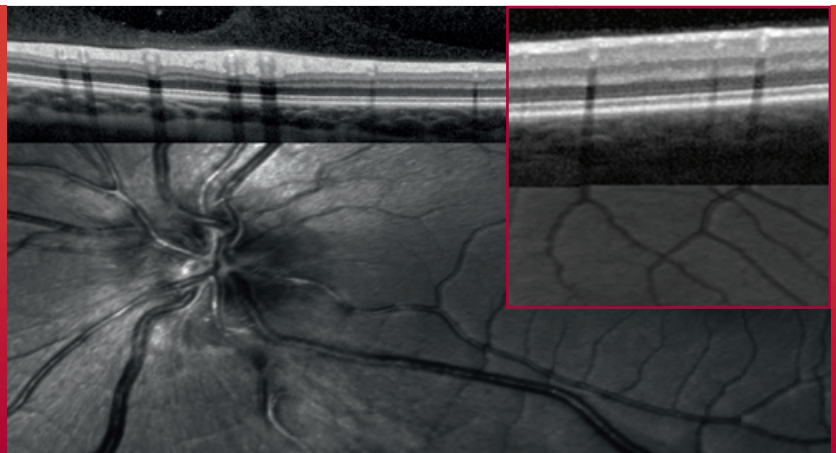


SPECTRALIS® is the combination of confocal scanning laser fundus imaging and Spectral-Domain OCT imaging. Actively guiding the OCT scan in real-time creates a new type of imaging: Tracking Laser Tomography. Any of the five fundus imaging modalities available on the system can be used to direct the Spectral-Domain OCT to an area of interest or across the entire posterior pole. This multi-modality imaging technology gives unprecedented insights into structure and function of the retina.

## The Precision of Active Eye Tracking

"Volume scanning is the real power of SD-OCT. Since very few patients can keep their eyes still during a volume scan, active eye tracking is essential to get accurate SD-OCT scans."

Alexander Walsh, MD



SPECTRALIS utilizes two separate beams of light to capture two images simultaneously. One beam constantly tracks and images the fundus. It also acts as a reference, guiding the OCT beam. Active Eye Tracking "locks" the OCT to the fundus. The precise alignment of blood vessels from fundus image to the corresponding OCT scan gives the proof. Active Eye Tracking is of critical importance in 3D volume scans which are susceptible to eye motion artifact.

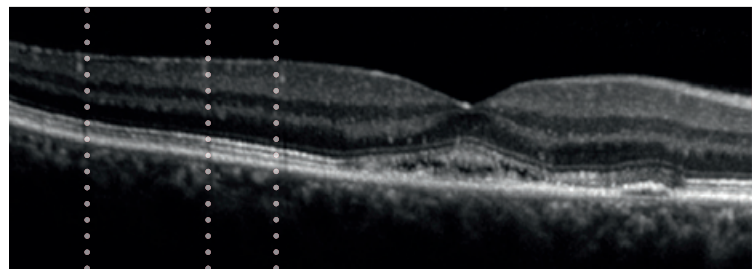
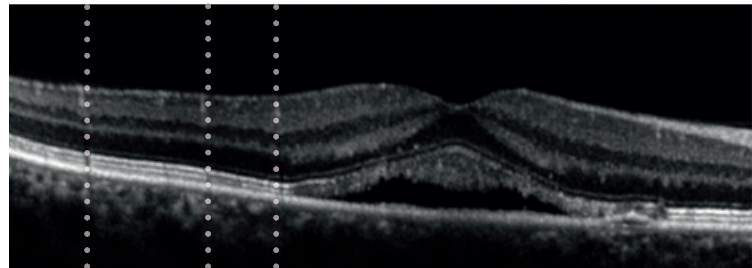
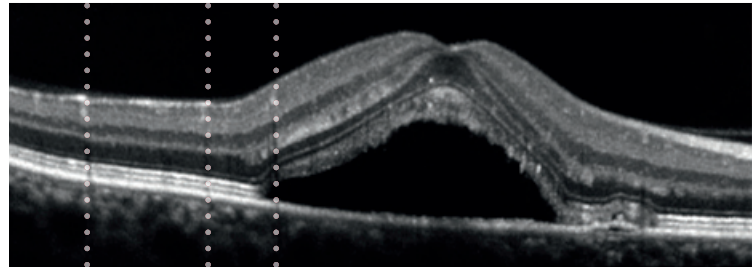
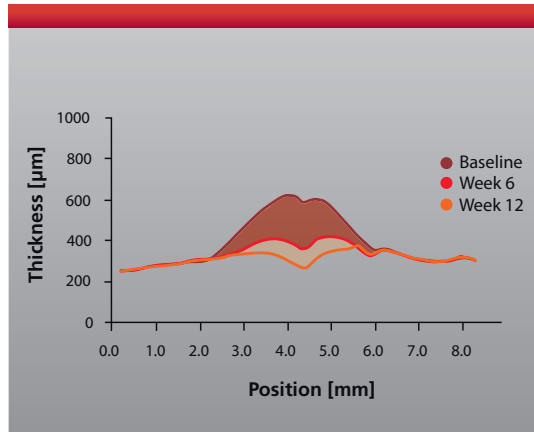
# Active Eye Tracking Makes the Difference

“It is crucial to know precisely what retinal area is being evaluated from visit to visit, and the eye tracking/image alignment provides that.”

Quan D. Nguyen, MD\*

**Tracking Change Over Time with AutoRescan™.** Knowing where the scan is taken the first time is important; knowing where the scan is taken at follow-up is critical. Using the fundus image like a fingerprint, SPECTRALIS automatically places follow-up scans in precisely the same location.

Eliminating subjective placement of follow-up scans is important for optimizing patient flow and for confidently identifying small change.



Blood vessel alignment across all visits demonstrates precise rescan placement.

Device	Smallest Measurable Change**
SPECTRALIS	1 $\mu\text{m}$
OCT SLO	5 $\mu\text{m}$
Stratus	7 $\mu\text{m}$
RTVue	7 $\mu\text{m}$
Copernicus	9 $\mu\text{m}$
Cirrus	9 $\mu\text{m}$

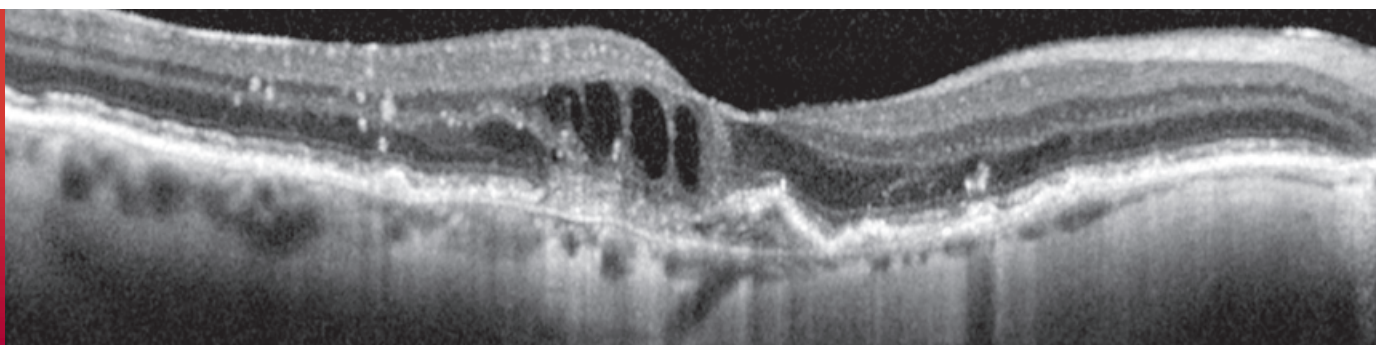
**Smallest Measurable Change.** Reliability of measurements is crucial to accurate diagnosis and effective management of glaucoma and retinal diseases. Active Eye Tracking makes the difference when it comes to repeatability and reproducibility of OCT measurements. In a head-to-head comparison of OCT instruments, SPECTRALIS had the lowest variability and smallest measurable change of 1 micron\*\*.

\* The views expressed by Dr. Nguyen do not necessarily reflect the views of the Johns Hopkins University or the Johns Hopkins Medical Institutions.

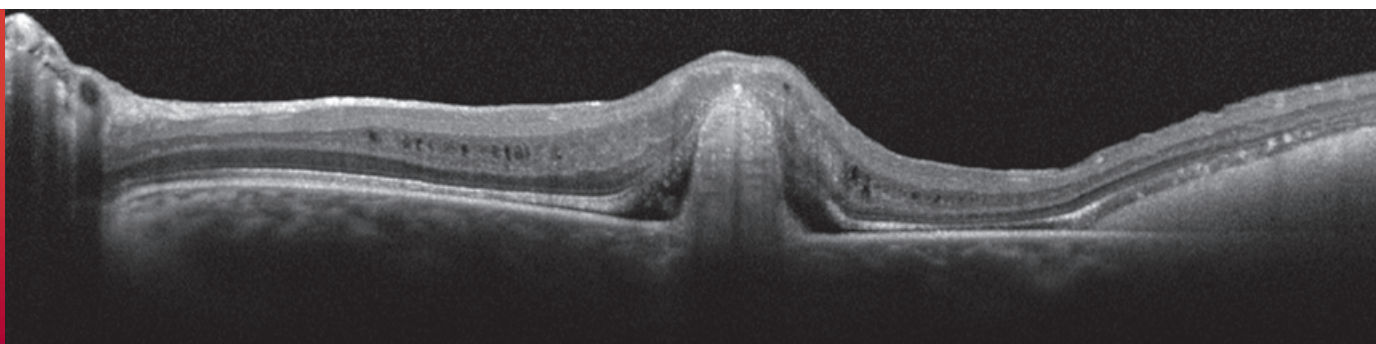
\*\* Wolf-Schnurrbusch et al. Invest Ophthalmol Vis Sci 2009; 50:3432-3437. Smallest Measurable Change is Central Retina Thickness multiplied by Coefficient of Variation. Results rounded to the nearest micron.

# In Vivo Optical Histology

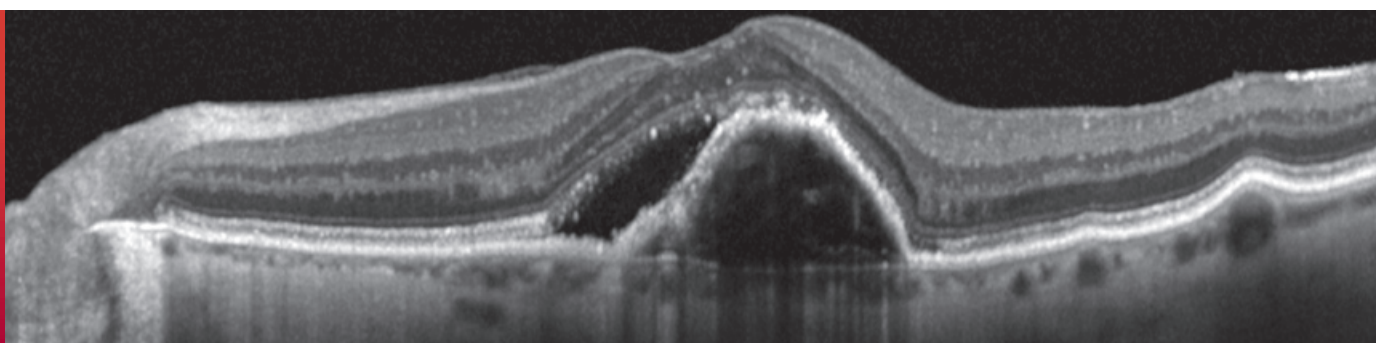
**The Insight of Heidelberg Noise Reduction™.** TruTrack™ Active Eye Tracking enables the capture of multiple images in the exact same location. The automatic real time (ART) combination of these images allows for effective discrimination between image “noise” and true signals from real tissue structures. Noise is effectively eliminated and the result are images of outstanding contrast and detail.



**CASE 1: AMD** — Exudative age-related macular degeneration with intraretinal fluid, retinal pigment epithelial and photoreceptor disruption.



**CASE 2: Best's Disease** — Presenting with a highly reflective nodular lesion protruding into the subretinal space; photoreceptor disruption on each side of the lesion and subtle areas of subretinal and intraretinal fluid are clearly displayed.



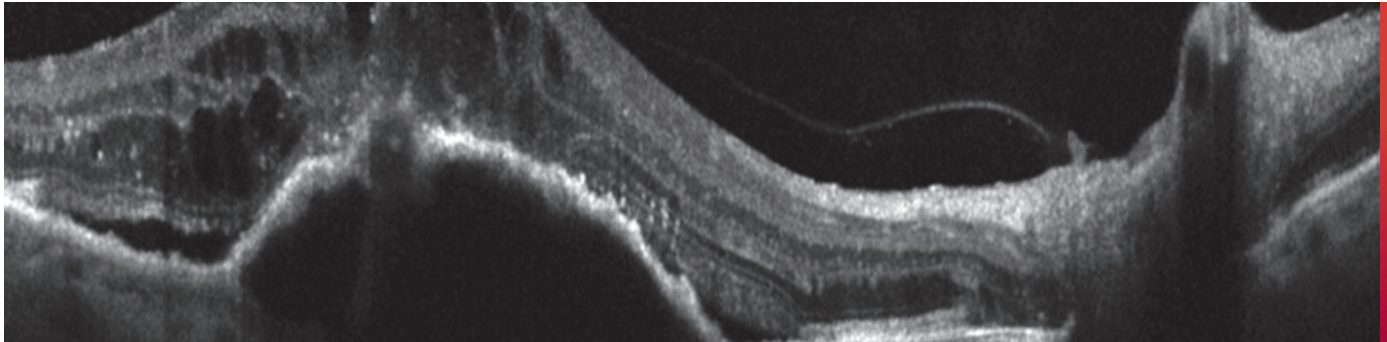
**CASE 3: CNV with PED** — Exudative macular degeneration manifest by a serous pigment epithelial detachment with overlying subretinal fluid.

“With Spectral-Domain OCT imaging, the specific histopathologic bands between the different retinal layers are visible in most patients. It’s like getting a noninvasive retinal biopsy.”

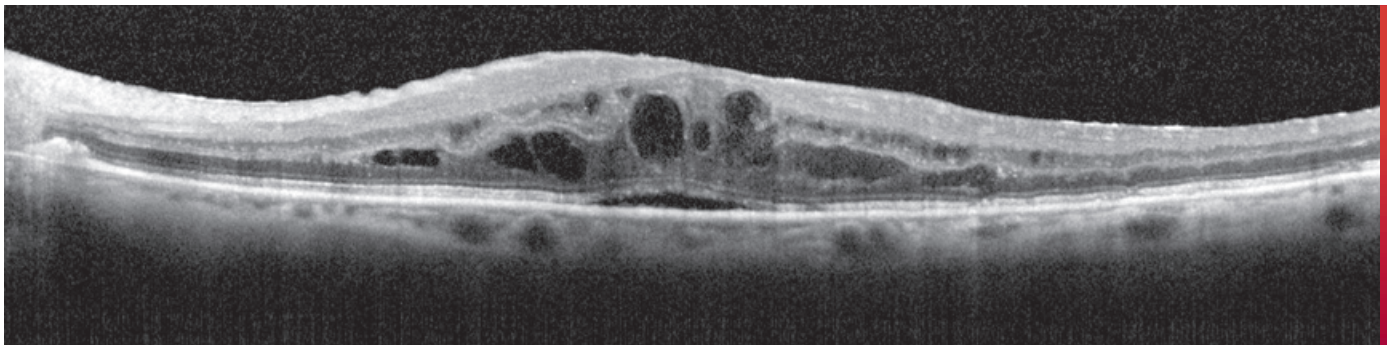
David M. Brown, MD

“The images show increased resolution across all retinal layers, especially at the RPE where subtle differences are especially meaningful.”

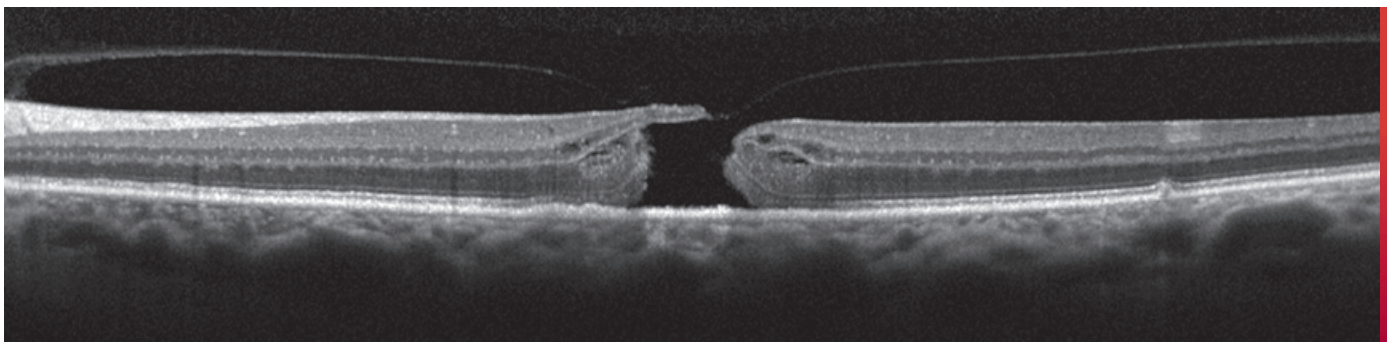
Jeff Heier, MD



**CASE 4: RAP Lesion** — Precise location of retinal angiomatous proliferation (retinal choroidal anastomosis) breaking through RPE, above a PED.



**CASE 5: CME** — Cystoid macular edema with clear delineation of affected layers of the retina, including subtle subretinal fluid, prominent accumulation of fluid in the outer plexiform layer, and subtle cystic changes in the inner plexiform layer.



**CASE 6: Macular Hole** — Stage 3 macular hole demonstrating full thickness macular defect, subtle intraretinal cystic changes, and attachment of the posterior hyaloid on the edge of the hole.

# Designed for Efficiency

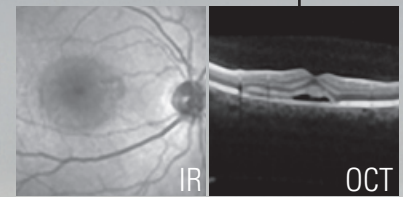
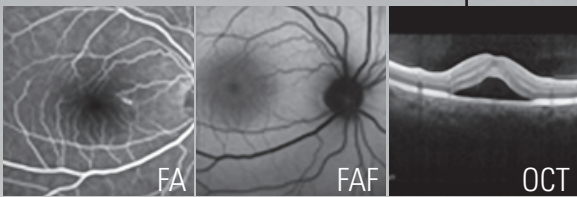
**Flexible Solutions for Patient Workflow and Patient Data.** Effective integration of diagnostic equipment in the clinical setting can significantly improve patient comfort, quality of care and, workflow efficiency.

SPECTRALIS was designed with the flexibility to integrate effectively into any clinical setting from a solo practice to a high volume clinic with multiple satellite offices. The HEYEX™ patient database facilitates storage and management of image files from most imaging devices. The Network Viewing software allows easy, reliable access to patient image files on any networked computer. TruTrack and the AutoRescan function allow follow-up scanning at any networked Spectralis device.

## Initial patient exam

## Follow-up exam

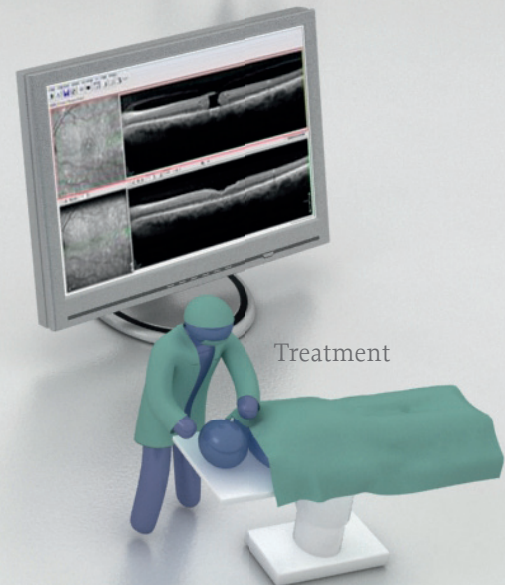
AutoRescan™

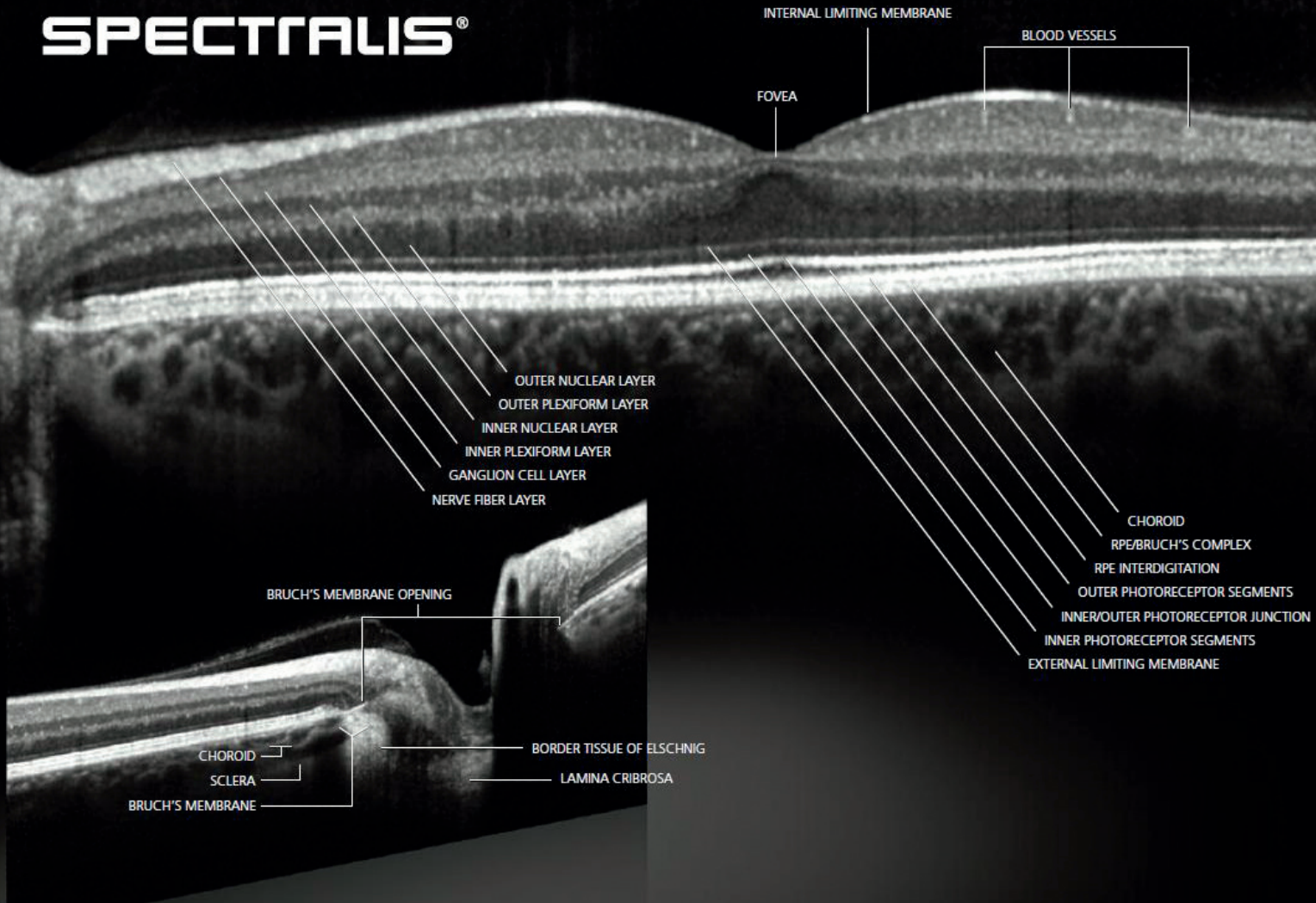


**HFA+OCT  
SPECTRALIS**  
Angiography room

**HEYEX**  
Common  
patient  
database

**OCT  
SPECTRALIS**  
Photography room





**Protect Your Investment.** All SPECTRALIS models include TruTrack Active Eye Tracking and Heidelberg Noise Reduction for precise, detailed imaging. In addition, many models offer upgrade paths that allow your imaging system to grow with your practice needs. The BluePeak™ enabled models add blue laser autofluorescence to provide insight into the health of the RPE/Photoreceptor complex non-invasively without the need to inject any dye.

SPECTRALIS						
	OCT	OCT <sup>PLUS</sup>	OCT <small>bluepeak</small>	OCT <sup>PLUS</sup> <small>bluepeak</small>	HRA <small>bluepeak</small>	HRA+OCT <small>bluepeak</small>
SD-OCT	■	■	■	■		■
Infrared Imaging	■	■	■	■	■	■
Blue Laser Autofluorescence			<small>bluepeak</small>	<small>bluepeak</small>	<small>bluepeak</small>	<small>bluepeak</small>
Red-Free Imaging					■	■
Fluorescein Angiography					■	■
ICG Angiography					■	■
Widefield Imaging		■		■	■	■
Peripheral OCT		■		■		■
Upgradeable to HRA + OCT		■		■	■	n/a
TruTrack™ Active Eye Tracking						
Noise Reduction Technology						



Heidelberg Engineering GmbH · Tiergartenstr. 15 · 69121 Heidelberg · Germany  
Tel. +49 6221 6463 0 · Fax +49 6221 646362 · [www.HeidelbergEngineering.com](http://www.HeidelbergEngineering.com)

USA

Heidelberg Engineering, Inc. · 1499 Poinsettia Avenue, Suite 160 · Vista, CA 92081  
Tel. +1 760-598-3770 · Fax +1 760-598-3060 · [www.HeidelbergEngineering.com](http://www.HeidelbergEngineering.com)